



CEREBROSPINAL FLUID LEAK (CSF LEAK)

INTRODUCTION

A hole or tear in the brain lining will result in a leak of fluid that normally surrounds the brain. This fluid is known as cerebrospinal fluid or “CSF.” Drainage of CSF into the sinuses (See Sinus Anatomy) can result in many problems. Most notably the annoying constant nasal dripping. This article discusses current thoughts on the causes and diagnosis of CSF leaks.

ANATOMY AND PHYSIOLOGY

CSF consists of a mixture of water, electrolytes, glucose, amino acids and various proteins. CSF is colorless, clear, and usually does not contain any cells. The primary site of CSF production is an area within the brain (choroid plexus). It is responsible for 50-80% of its daily production. CSF is produced at a rate of around 20 mL/hr for a total of around 500 mL daily. At any given time, there is around 90-150 mL of CSF moving around the brain and spinal cord.

CAUSES

In the adult patient, it is helpful to classify CSF leaks into two categories. One is spontaneous CSF leaks. The other is CSF leaks caused by injury to the bone separating the brain and the nose (See Skull Base Anatomy). These include CSF leaks that are caused by trauma, surgery and tumors.

Accidental Trauma: Penetrating and closed-head trauma cause 90% of all cases of CSF leaks. CSF leaking out of the nose following trauma is classified as immediate (within 48 hours) or delayed. Most traumatic CSF leaks are immediate. Of patients with delayed CSF leaks, 95% present within 3 months after the injury.

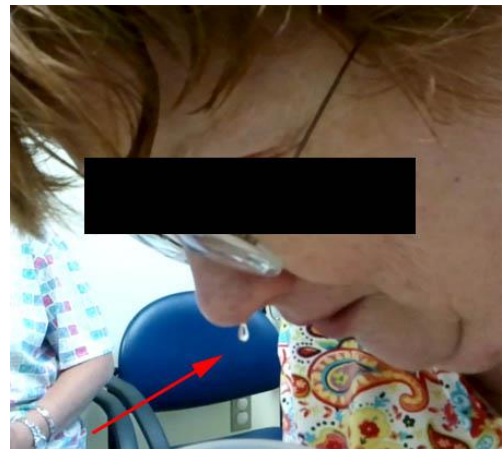
Surgical Trauma: Surgical trauma can occur during sinus or brain surgery (See Endoscopic Sinus Surgery). These injuries occur along the bone separating the sinuses from the brain and through the lining of the brain. Skull base injuries vary from simple cracks in the bone to large holes with potential injury to the brain.

Tumor-related CSF Rhinorrhea: It is uncommon for the growth of non-cancer tumors (See Sinus Tumors) to result in CSF leaks. However, aggressive benign tumors (such as inverted papilloma) and cancers can either erode or invade the bone of the skull base. The breakdown of the bone results in breakdown of these barriers. Frequently the removal of these tumors results in a CSF leak that is repaired at the time of the surgery.

Spontaneous CSF Rhinorrhea: Spontaneous CSF leaks occur in patients without any of the previous causes discussed. Spontaneous CSF leaks are probably due to elevated intracranial pressure (ICP). Intracranial pressure is a different pressure from blood pressure. The causes of elevated ICP can be multiple. Once elevated ICP develops, the pressure placed on the skull base results in thinning of the bone. Ultimately, the bone is weakened until a hole is formed and a leak begins. The brain lining or a part of the brain may poke through the weakened part of the bone (known as a meningocele or encephalocele).

CLINICAL

History: A complete history is the first step towards an accurate diagnosis. CSF leaks usually present as clear, watery discharge on one side of the nose. It is usually constant but it may stop and start with certain activities. This drainage can be caused by bending over or by straining. Patients may report a metallic or salty taste. Many patients with spontaneous leaks are wrongly diagnosed with allergies or sinus infections. Patients with recurrent meningitis (multiple episodes), especially pneumococcal meningitis, should be tested for a CSF leak, regardless of the presence of active clear nasal discharge. A history of headaches (See Headaches and Sinus Disease), ringing in the ears and blurry vision may suggest increased ICP. MRI and CT imaging of the brain may reveal signs of increased intracranial pressure. This can be shown and described to you by your surgeon.



Physical Exam: Physical examination includes a complete head and neck examination. Nasal endoscopy (looking further into the nose and sinuses with an endoscope) is very helpful. Examination may reveal clear discharge, a skull base defect (if traumatic or surgically caused) or a mass. In many cases, however, examination is normal and the physician must base his or her decisions on history alone.

In patients with head trauma, the mixture of blood and CSF may make the diagnosis difficult. CSF mixed with blood forms a “halo sign” when dripped on filter paper. A “halo sign” can be described as a clear ring of fluid surrounding a central area of blood. However, the presence of a halo sign is not specific to CSF and can lead to false-positive results.

WORKUP

There are many laboratory and imaging studies that can be ordered to confirm the presence of a CSF leak. The ones listed here are the most common.

Lab Studies

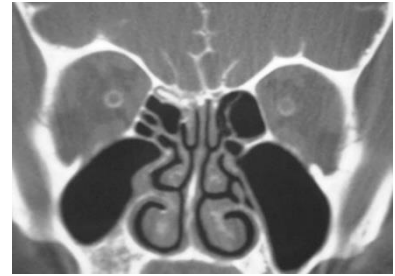
1. Beta-2 transferrin

- Beta2-transferrin is a protein found in CSF, but not in normal nasal discharge. If a CSF leak is present it can be identified in a sample of a patient’s nasal fluid.
- Beta-2 transferrin is stable at room temperature for approximately 4 hours. Patients must store the collected fluid in a refrigerator as soon as possible. Specimens should not be frozen.
- Beta-2 transferrin is the single best lab test for identifying the presence of CSF in nasal fluid.

Imaging Studies

1. Computed Tomography (CT) scanning

- High-resolution CT scanning is the best form of diagnostic imaging for identifying a CSF leak.
- CT scans may show skull base defects resulting from trauma, anatomic or developmental abnormalities, or a tumor.



2. Magnetic Resonance Imaging (MRI)

- Unlike CT scanning, MRI does not show bone well; therefore, it is difficult to see cracks in the skull base bone.
- MRI is not the first line imaging method in the evaluation of CSF leaks. It can be helpful if a tumor or mass is seen on exam or suspected.

3. CT Cisternography

- Sometimes a CT scan can be improved by injecting contrast into the spinal canal (this is called a cisternogram).
- CT cisternography can show the precise location of a CSF leak in most patients who have active clear nasal drainage.
- The disadvantages of CT cisternography is that the patient must be actively leaking CSF. If it is only an intermittent CSF leak it may not show up. Also, patients need to have a spinal tap in order to have the procedure.

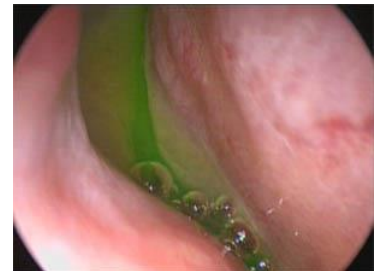4. Nuclear Medicine Studies

- Nuclear isotopes (substances in the body that we can trace) are injected into the spinal canal. These isotopes may then leak into the nose or sinuses and collect on cotton pads inserted into the nose. After a number of hours, these pads are removed and analyzed for the presence of these nuclear isotopes.
- This study is safe, but it cannot precisely identify the location of the leak. This study is incorrectly positive for a CSF leak in as many as 33% patients. This procedure is generally not recommended.

DIAGNOSTIC PROCEDURES

The injection of a dye (fluorescein) into the spinal canal has been used to diagnose and localize CSF leaks.

1. The US Food and Drug Administration has not approved the use of fluorescein for CSF leaks. However, when used properly it is safe.
2. A small volume of the patient's own CSF is collected via a spinal tap. Then a very small amount of fluorescein is mixed into this CSF and placed back into the patient. The fluorescein can also be mixed with sterile, preservative-free saline (salt water) and used in this way as well.
3. Nasal endoscopy is performed approximately 30-60 minutes after the fluorescein mixture is injected.
4. In most instances of CSF leak, fluorescein is seen in the nose and sinuses during nasal endoscopy. It appears as a bright neon green-yellow liquid. However, very small defects may leak only a very small amount and may be difficult to observe.



SUMMARY

There are a number of causes of CSF Leak. Once the presence of a CSF leak is confirmed, a treatment plan will be recommended by your physician (See CSF Leak Repair).

Copyright © 2020 by The American Rhinologic Society

The American Rhinologic Society presents this information as a service to current, past and future patients of its members as well as its membership. All information is believed to be accurate and true. Diligent efforts have been made to ensure objectivity and balance. The American Rhinologic Society, its Board of Directors, its Officers, its representatives, and its members are not responsible for any errors and/or omissions. The American Rhinologic Society cannot provide specific medical advice to patients via the Internet. All patients are encouraged to direct their specific questions to their personal physicians. The American Rhinologic Society presents this information for patients so that patients can understand and participate in their own medical care